Jpn. J. Cancer Res. 91, 1345–1349, December 2000

Atypical Osteosarcomas in Werner Syndrome (Adult Progeria)

Yuichi Ishikawa,[1,4] Robert W. Miller,[2] Rikuo Machinami,[1] Haruo Sugano[1] and Makoto Goto[3]

[1]*Department of Pathology, The Cancer Institute, 1-37-1 Kami-Ikebukuro, Toshima-ku, Tokyo 170-8455,* [2]*Clinical Genetics Branch, National Cancer Institute, Bethesda, Maryland 20892-7236, USA and* [3]*Division of Rheumatic Diseases, Tokyo Metropolitan Otsuka Hospital, 2-8-1 Minami-Otsuka, Toshima-ku, Tokyo 170-0005*

Werner syndrome (WS), adult progeria, is more common in Japan than elsewhere. It predisposes to osteosarcoma (OS) and five other rare tumors. To determine if and how OS is atypical in this genetic disorder, we studied the characteristics of ten Japanese cases with respect to clinical features, pathology, and radiographs, and compared them with a hospital series of 36 skeletal OS with the same atypical age-range, 35–57 years. The anatomic sites were also atypical: seven ankle/foot, two radius and one patella compared with only one at the ankle in the hospital series. The osteoblastic cell-type was about equally frequent in both series, but, among others than the three major subtypes, there was only one in WS as compared with 14 (39%) in the hospital series. The types of mutations were sought in five WS cases with OS. One showed no mutation at any of the ten known loci for Japanese, two were of type 4/4 and two of type 6/6. The mutations 4 and 6 have been found in 66% of alleles of WS cases in Japan. The increased frequency and unusual age and site distributions of OS in WS may be due to increased susceptibility, related to later-life leg ulcers, and weight-bearing on spindly ankles weakened by severe loss of lower limb subcutaneous tissue.

Key words: Osteosarcoma — Werner syndrome — Pathology — Premature aging — Cancer predisposed syndrome

Werner syndrome (WS), or adult progeria, is a hereditary disease characterized by accelerated aging, including cataracts, gray hair, skin atrophy, and atherosclerosis.[1] Linkage analysis revealed that the responsible gene (*WRN*) was localized to 8p12,[2] which was identified by positional cloning.[3] About 80% of cases worldwide are Japanese, which is probably due to inbreeding (60% of our cases are inbred) and to the background high rate of *WRN* mutations in Japan.[4] Based on a survey of the literature and summarizing our own cases we found that, instead of the accelerated occurrence of ordinary cancers, the syndrome had a high risk of a spectrum of rare neoplasms: i) non-epithelial malignant or pre-malignant tumors/conditions, osteosarcomas (OS) and soft tissue sarcomas, malignant melanomas, myeloid leukemia and myelodysplastic syndrome; ii) an epithelial neoplasm, thyroid carcinoma, and iii) meningiomas, though all but one of 16 were reported to be benign.[5] Malignant melanomas and thyroid carcinomas have been reported only in Japanese with WS.[6] Common carcinomas of the aged, e.g., lung, colon and prostate, were rare.

OS occurs excessively in genetic disorders such as Li-Fraumeni syndrome,[7] Rothmund-Thomson syndrome[8] and after retinoblastoma.[9] There have been very few case-reports of skeletal OS in WS in the literature. OS arising in WS may be atypical, a common feature of genetic syndromes with excesses of cancer.[10] Additionally, OS rates climb in elderly Caucasians due to Paget's disease, but not in Japanese who rarely have this disorder.[11]

CASES AND METHODS

Our tumor files contain information on about 900 Japanese WS patients, covering 1966–1997, ascertained from published case-reports or cases seen by one of us (MG).[5] Diagnosis of WS was based on the presence of three out of four criteria under age 35: unusual body habitus (short stature and stocky trunk with spindly limbs); premature senescence (graying and loss of hair, cataracts, osteoporosis, and arteriosclerosis); scleroderma-like skin changes; and endocrine disorders (diabetes mellitus or hypogonadism).[12]

In addition, we examined X-ray films and tomographic images such as CT and MRI, as well as detailed family histories and pathology slides obtained from the physicians in charge of the patients. We confirmed the diagnoses of OS, based on the WHO classification[13] through review of all the collected materials.

Histological subtypes were chiefly based on Dahlin's criteria.[14] We compared our 10 cases with a hospital series of 36 consecutive cases of skeletal OS in the same age-range diagnosed at the Cancer Institute Hospital (CIH), Tokyo, 1978–1997. The orthopedic department of CIH gathers patients from all over Japan and treats the largest number of bone and soft-tissue sarcomas in Japan.

Germline mutations of *WRN* were examined using peripheral blood samples in five patients by methods pre-

[4] To whom correspondence should be addressed.
E-mail: 1967-bsi2@umin.ac.jp

viously described.[15] Each mutation (designated mutations 1–19) was referred to as previously summarized.[6] The study regarding mutation analysis using patients' blood was approved by our institutional review board and informed consent was obtained by doctors in charge.

RESULTS

Ten patients had histologically verified OS (Table I). We excluded the two youngest cases (17- and 20-year old females) reported previously[5] because of uncertainty about the diagnosis of WS in the first, and the absence of histologic slides for the other (the hospital had closed).

The age-range at diagnosis of OS was from 35 to 57 years (Table II), with a sex ratio of 1:1, as in the comparison group. Seven (70%) were in the ankle or foot, as compared with only one (3%) in the hospital series (Fig. 1). Two of the ten in our series affected the radius as compared with none in the comparison group.

The cell-type of five (50%) cases was osteoblastic as compared with 14 (39%) in the hospital series. Only one in the case series (10%) was among others than the three major subtypes, whereas 14 (39%) in the comparison group were. Other subtypes include well-differentiated, telangiectatic, small-cell, epithelioid, and malignant fibrous histiocytoma-like OS.

Five of the ten cases developed other cancers (Table I), and among them, three had two cancers in addition to OS. Six of the ten cases were known to be consanguinous (Table I). WS had affected the father and brother of case 3 and the brother of case 7. Reliable data were not available for cancer in relatives, but the father of case 3 was known to have had WS and stomach cancer. The positions of the *WRN* mutations could be identified in five cases (Table I). Two cases showed type 4/4, two 6/6, and one had no mutation at any of the ten known loci for Japanese.[15] Among Japanese with WS, the commonest mutations are types 4 and 6, which account for two-thirds of all mutated alleles (83/174+31/174=0.66).[6]

Table II. Histological Subtypes of Osteosarcoma in Werner Syndrome and the Comparison Group (Hospital Series)

	Werner syndrome	Comparison group
No. of cases	10	36
Age range (years)	35–57 (mean 48.0)	35–57 (mean 45.3)
Gender (F:M)	5:5	18:18
Histological subtype		
Osteoblastic	5 (50%)	14 (39%)
Chondroblastic	2 (20%)	4 (11%)
Fibroblastic	2 (20%)	4 (11%)
Other[a]	1 (10%)	14 (39%)

a) Including well-differentiated, telangiectatic, small-cell, MFH (malignant fibrous histiocytoma)-like subtypes and so forth.

Table I. Osteosarcomas (OS) Arising in Werner Syndrome in Japan

Case no.	Patient ID no.	Sex[a]	Ages at Dx of OS[b]	Skeletal site	Subsite	Histological subtype	Mutation[c]	Other cancers (age)	Consanguinity	Ref.
1.	20001	F	35	Patella	—	Osteoblastic	4/4	Thyroid, follicular (27) Uterus, NOS[d] (34)	Yes	21)
2.	6104	M	37	Radius	Diaphysis	Fibroblastic	4/4		No	22)
3.	20201	M	45	Tibia	Distal	Fibroblastic	n.e.[e]	Thyroid, papillary (45) Leiomyosarcoma, lung (45) Melanoma, foot (45) Gastric carcinoma (45)	No	23)
4.	22801	M	47	Radius	Distal	Chondroblastic	n.e.		Yes	24)
5.	22901	F	49	Tibia	Distal	Osteoblastic	n.e.		No	25)
6.	20101	F	49	Fibula	Distal	Chondroblastic	n.e.	Thyroid, papillary (40)	No	26)
7.	15001	M	50	Tibia	Distal	Osteoblastic	6/6	Melanoma, eye conjunctiva (50)	Yes	27)
8.	16301	F	55	Calcaneus	—	Osteoblastic	6/6		Yes	28)
9.	23001	F	56	Fibula	Distal	Osteoblastic	n.e.		Yes	29)
10.	26401	M	57	Calcaneus	—	Well-diff.	?/?	MFH[f] (50) Spindle cell sarcoma (47)	Yes	30)

a) M: male, F: female.
b) Ages: at diagnosis of OS.
c) Mutations: see text.
d) NOS: not otherwise specified.
e) n.e.: not examined.
f) MFH: malignant fibrous histiocytoma.

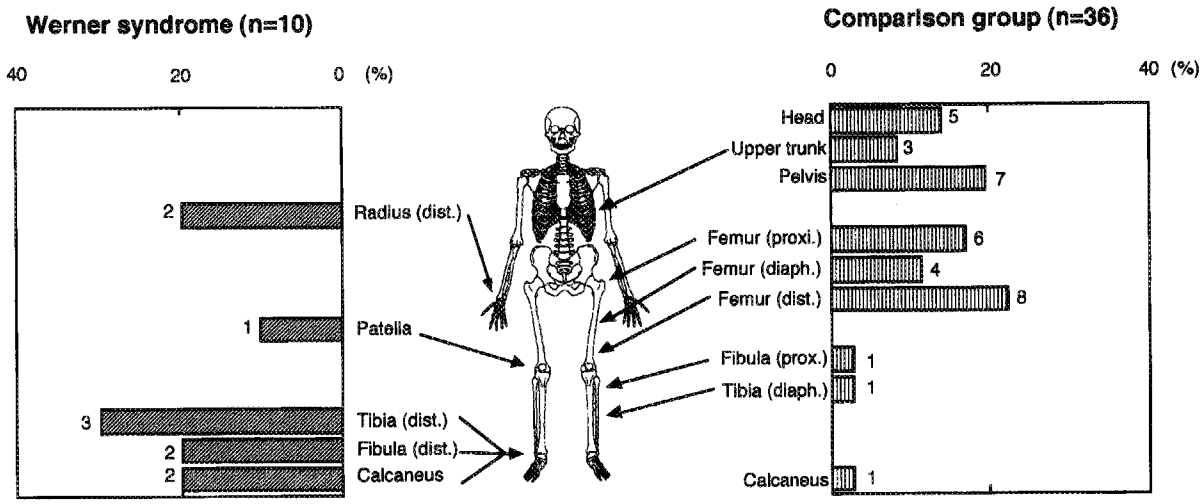

Fig. 1. Comparisons of subsites of osteosarcomas arising in Werner syndrome and in the comparison group (hospital series from the Cancer Institute Hospital).

DISCUSSION

It is known that OS in adults has different characteristics from those in young people; no high peak of incidence, no preferential site of occurrence (adolescent OS occurs mostly at knees and proximal humerus), less osteoblastic cell type and no male predominance.[14] We previously pointed out that the incidence of adult OS is less in Japan than in US, probably due to the rarity of Paget's disease in Japan, although the adolescence peak is strikingly similar.[11] The age distribution of our cases with WS and OS (in middle age) is unlike those of the general populations of Japan and the USA, which have peaks in adolescence.[11] The sexes were equally affected in the cases and the hospital series. The distribution of OS by skeletal site was unusual in all ten patients with WS. Seven of ten cases (70%) were at the foot/ankle, as compared with 3% (1/36) in our hospital series and 3.8% (62/1649) in Dahlin's series.[14] OS of the radius affected two of our WS patients (20%) versus none (0%) in our hospital series and only 1% (17/1649) of Dahlin's cases. Our ten OS cases show a slightly different spectrum of histological subtypes (Table II). This may have some implications for the pathogenesis of the tumor because it was previously demonstrated that "atypical" OS (arising in short and flat bones) shows subtypes other than the three major histologies more often than "typical" OS (arising in long bones).[16]

Among Caucasians with WS, there have been only three case reports of skeletal OS in the literature, and two of three cases were of rare sites, small bones of the foot in one case[17] and the distal tibia/fibula in another.[18] These findings replicate those of the Japanese concerning the predisposition to OS of the ankle/foot in WS.

Histologically confirmed OS occurred in at least (these) ten of, say, 4000 Japanese with WS during 1966–1995, perhaps a high estimate. Four thousand is four times greater than the number of WS in our registry, and seven times the number based on the estimated gene frequency in Kanagawa Prefecture.[4] In this area, which includes Yokohama, the gene frequency indicated that, if it were the same throughout Japan, there would be 23 births annually of persons destined to develop WS.[4] This means that (disregarding losses due to death) the number of persons at risk of WS-related OS at ages 35–59 from 1966–1995 would be 23 cases multiplied by 25 birth years, which is 575 persons. The annual incidence of OS in Osaka, Japan, at ages 25–64 was 0.49/100 000 in 1983–1987.[19] Less than one case would be expected if there were 4000 Japanese with WS over a 30-year interval (120 000 person-years at risk). There is, thus, an excess of OS in WS, but it is atypical.

Parry *et al.*[10] have noted that germline mutations may be related to cancer with atypical features; that is, they differ from usual in their distributions by age, gender, anatomic site and/or histologic type. In WS the most pronounced departures are the age at diagnosis and the anatomic site affected. The marked difference of anatomic sites between WS and the comparison group raises questions about the pathogenesis of OS in WS. The legs are affected at older ages by ulcers, gangrene, and wasting of soft tissue. The ankles are very thin. Thus, the genetic disorder causes anatomic changes that concentrate weight-bearing at the ankle which perhaps leads to OS in a predisposed host. The vulnerability in WS is indicated by the reports of OS at other unusual sites in Japanese (two radius, one patella).

Additionally, WS patients develop malignant melanoma of the feet: 13 cases observed versus one expected.[5] Feibleman *et al.*[20] studied the distribution of melanoma of the feet, and observed that the frequency was highest at places where weight-bearing was greatest. The concurrence of clusters of two types of cancer at the ankle/foot suggests a pathogenesis in common. It may be that among genetic disorders with high risk of OS, the excess at the ankle/foot occurs only in WS because of its late-stage wasting of the legs.

ACKNOWLEDGMENTS

This binational collaboration was developed from a workshop on cancer clusters held by the US-Japan Cooperative Cancer Research Program in Santa Fe in March 1994. Parts of this study were financially supported by Grants-in-Aid for Scientific Research (including Priority Areas for Cancer Research) from the Ministry of Education, Science, Sports and Culture, Japan. We thank doctors in charge of the cases presented in the collaboration in the collection of materials and information: Dr. M. Hino, Kobe City General Hospital; Prof. S. Maeda, Kobe University; Dr. A. Hatamochi, Chiba University; Dr. H. Tsuchiya, Kanazawa University; Dr. A. Suda, Yamagata University; Dr. H. Sakihara, Eiju General Hospital; Dr. H. Tanaka, Shizuoka General Hospital; Drs. H. Nishimoto and K. Shimokawa, Gifu University; Dr. Y. Tsuji, Yokaichi National Hospital; Dr. K. Shinohara, Kochi National Hospital; and Drs. Y. Nakamura and K. Yoshimura, Shinshu University. We are also grateful for collaboration in mutation analysis by Drs. T. Matsumoto and Y. Furuichi, Agene Research Institute, Kamakura, Japan.

(Received July 27, 2000/Revised September 20, 2000/Accepted September 25, 2000)

REFERENCES

1) Goto, M. Hierarchical deterioration of body systems in Werner's syndrome: implications for normal ageing. *Mech. Ageing Dev.*, **98**, 239–254 (1997).
2) Goto, M., Rubenstein, M., Weber, J. and Drayna, D. Genetic linkage of Werner's syndrome to five markers on chromosome 8. *Nature*, **355**, 735–738 (1992).
3) Yu, C. E., Oshima, J., Fu, Y. H., Wijsman, E. M., Hisama, F., Alisch, R., Matthews, S., Nakura, J., Miki, T., Ouais, S., Martin, G. M., Mulligan, J. and Schellenberg, G. D. Positional cloning of the Werner's syndrome gene. *Science*, **272**, 258–261 (1996).
4) Satoh, M., Imai, M., Sugimoto, M., Goto, M. and Furuichi, Y. Prevalence of Werner's syndrome heterozygotes in Japan. *Lancet*, **353**, 1766 (1999).
5) Goto, M., Miller, R. W., Ishikawa, Y. and Sugano, H. Excess of rare cancers in Werner syndrome (adult progeria). *Cancer Epidemiol. Biomarkers Prev.*, **5**, 239–246 (1996).
6) Ishikawa, Y., Sugano, H., Matsumoto, T., Furuichi, Y., Miller, R. W. and Goto, M. Unusual features of thyroid carcinomas in Japanese patients with Werner syndrome and possible genotype-phenotype relations to cell type and race. *Cancer*, **85**, 1345–1352 (1999).
7) Li, F. P, Fraumeni, J. F., Jr., Mulvihill, J. J., Blattner, W. A., Dreyfus, M. G., Tucker, M. A. and Miller, R. W. A cancer family syndrome in twenty-four kindreds. *Cancer Res.*, **48**, 5358–5362 (1988).
8) Vennos, E. M. and James, W. D. Rothmund-Thomson syndrome. *Dermatol. Clin.*, **13**, 143–150 (1995).
9) Draper, G. J., Sanders, B. M. and Kingston, J. E. Second primary neoplasms in patients with retinoblastoma. *Br. J. Cancer*, **53**, 661–671 (1986).
10) Parry, D. M., Mulvihill, J. J., Miller, R. W., Berg, K. and Carter, C. L. Strategies for controlling cancer through genetics. *Cancer Res.*, **47**, 6814–6817 (1987).
11) Ishikawa, Y., Tsukuma, H. and Miller, R. W. Low rates of Paget disease of bone and osteosarcoma in elderly Japanese. *Lancet*, **347**, 1559 (1996).
12) Goto, M., Horiuchi, Y., Tanimoto, K., Ishii, T. and Nakashima, H. Werner's syndrome: analysis of 15 cases with a review of the Japanese literature. *J. Am. Geriatr. Soc.*, **26**, 341–347 (1978).
13) Schajowicz, F. "Histological Typing of Bone Tumours," 2nd Ed., pp. 1–128 (1993). WHO International Histological Classification of Tumours, Springer, Berlin.
14) Unni, K. K. "Dahlin's Bone Tumors," 5th Ed., pp. 1–463 (1996). Lippincott-Raven, Philadelphia.
15) Matsumoto, T., Imamura, O., Yamabe, Y., Kuromitsu, J., Tokutake, Y., Shimamoto, A., Suzuki, N., Satoh, M., Kitao, S., Ichikawa, K., Kataoka, H., Sugawara, K., Thomas, W., Mason, B., Tsuchihashi, Z., Drayna, D., Sugawara, M., Sugimoto, M., Furuichi, Y. and Goto, M. Mutation and haplotype analyses of the Werner's syndrome gene based on its genomic structure: genetic epidemiology in the Japanese population. *Hum. Genet.*, **100**, 123–130 (1997).
16) Machinami, R., Imamura, T., Takeyama, S. and Tateishi, A. Typical and atypical osteosarcomas: a clinicopathologic study of sixty-two cases. *Gann*, **70**, 621–638 (1979).
17) McKusick, V. A. Medical genetics. *J. Chronic Dis.*, **16**, 600 (1963).
18) Rosen, R. S., Cimini, R. and Coblentz, D. Werner's syndrome. *Br. J. Radiol.*, **43**, 193–198 (1970).
19) Parkin, D. M., Muir, C. S., Whelan, S. L., Gao, Y. T., Ferlay, T. and Powell, J. "Cancer Incidence in Five Continents," IARC Scientific Publ. No. 120, pp. 498–501 (1992). IARC, Lyon.
20) Feibleman, C. E., Stoll, H. and Maize, J. C. Melanomas of the palm, sole, and nailbed: a clinicopathologic study. *Cancer*, **46**, 2492–2504 (1980).
21) Ozawa, M., Arita, D., Hino, M., Ko, T., Ishihara, T., Moridera, K., Kurahachi, H. and Oogo, N. A case of

Werner's syndrome associated with uterine cancer, thyroid cancer and osteosarcoma. *Pharma Medica*, **8**, 137 (1990) (in Japanese).

22) Murata, K., Hatamochi, A., Shinkai, H., Ishikawa, Y., Kawaguchi, N. and Goto, M. A case of Werner's syndrome associated with osteosarcoma. *J. Dermatol.*, **26**, 682–686 (1999).

23) Tsuchiya, H., Tomita, K., Ohno, M. and Kawashima, A. Werner's syndrome combined with quintuplicate malignant tumors: a case report and review of literature data. *Jpn. J. Clin. Oncol.*, **21**, 135–142 (1991).

24) Yokota, M., Suda, A., Sato, R., Ishikawa, A. and Miura, Y. A case of Werner's syndrome with osteosarcoma of the radius. *Clin. Orthop. Surg.*, **26**, 1411–1414 (1991) (in Japanese).

25) Sakihara, H., Ogawa, S., Wada, N. and Yasui, S. A case of Werner's syndrome associated with osteosarcoma of the tibia. *J. Jpn. Orthop. Assoc.*, **66**, S1038 (1992) (in Japanese).

26) Ichioka, S., Tanaka, H., Uchiyama, K. and Yamada, A. A case of Werner's syndrome associated with double cancer. *Jpn. J. Plast. Reconstr. Surg.*, **34**, 975–982 (1991) (in Japanese).

27) Nishimoto, H., Ohno, T., Matsunaga, T., Hirosumi, Y., Kachi, H., Horiya, Y., Kakumu, M., Shiokawa, K. and Takeuchi, S. A case of Werner's syndrome with osteosarcoma. *J. Tokai Bone Soft Tissue Tumors*, **7**, 36–37 (1996) (in Japanese).

28) Tsuji, Y., Kusuzaki, K., Kanemitsu, K., Matsumoto, T., Ishikawa, Y. and Hirasawa, Y. Calcaneus osteosarcoma associated with Werner syndrome: a case report with mutation analysis. *J. Bone Joint Surg. Am.*, **82**, 1308–1313 (2000).

29) Matsushige, N., Uemura, N., Kono, R., Hayashi, T., Inoue, S., Matsuda, Y., Kishi, S. and Shinohara, S. A case of Werner's syndrome associated with osteosarcoma. *Med. J. Kochi Natl. Hosp.*, **3**, 35–38 (1994) (in Japanese).

30) Nakamura, Y., Shimizu, T., Hisa, K., Yoshimura, K. and Takaoka, K. A case of Werner syndrome associated with multiple sarcoma. *J. Jpn. Orthop. Assoc.*, **72**, S1053 (1998) (in Japanese).