ONCOLOGY REPORTS 6: 965-968, 1999

Expression of cyclooxygenase-2 in human adenocarcinomas of the gastric cardia and corpus

DUMINDA RATNASINGHE[1], JOSEPH A. TANGREA[1], MARK J. ROTH[1], SANFORD M. DAWSEY[1], MARIAM ANVER[2], BARBARA A. KASPRZAK[2], NAN HU[1], QUAN-HONG WANG[3] and PHILIP R. TAYLOR[1]

[1]Division of Clinical Sciences, National Cancer Institute, NIH, Bethesda, MD; [2]Pathology/Histotechnology Laboratory, SAIC, National Cancer Institute, Frederick Cancer Research and Development Center, Frederick, MD, USA; [3]Department of Pathology, Shanxi Cancer Hospital, Taiyuan, China

Received February 26, 1999; Accepted March 29, 1999

Abstract. Several studies indicate that the use of non-steroidal anti-inflammatory drugs (NSAIDs) may reduce the risk of gastric corpus and possibly gastric cardia cancers. The best known action of NSAIDs is to block the enzyme cyclooxygenase, the rate limiting enzyme in the conversion of arachidonic acid to prostaglandins. We investigated the expression of cyclooxygenase-2 (Cox-2) in adenocarcinomas of the gastric cardia (N=19) and corpus (N=15) and in adjacent normal epithelium from a high risk Chinese population. Immunohistochemical detection of Cox-2 revealed positive staining in 36% of the gastric cardia cancer cases and 60% of the gastric corpus cancer cases, whereas histologically normal tissue from the same patients were negative. Smooth muscle, stroma and inflammatory cells were also positive. Our results suggest that Cox-2 is over-expressed in a large proportion of adenocarcinomas of the gastric corpus and in a smaller number of gastric cardia cancer cases.

Introduction

Cancer of the gastric corpus continues to be a major world health problem and the second most frequent cancer despite its decline in incidence (1,2). Early detection of stomach cancer is difficult, and in most Western countries the five-year survival rate is less than 20% (3). More than 90% of gastric cancers are adenocarcinomas and their pathogenesis is quite complex. While the overall incidence of gastric cancer involving the body of the stomach has declined in industrialized nations, there has been an unexplained rise in adenocarcinoma of the proximal or cardiac region of the stomach over the last 10-15 years in Western countries. The highest incidence of upper gastrointestinal tract cancers occur in Northern China (4). Thus, the development of strategies to prevent gastric corpus and gastric cardia cancers, including chemopreventive agents, may prove beneficial.

In a large prospective mortality study (5), the use of aspirin was associated with a reduced risk of cancers of the stomach, esophagus and colorectum compared to non-users. More recently, Farrow and colleagues (6) reported that current users of aspirin were at reduced risk for gastric corpus adenocarcinoma [odds ratio (OR), 0.46; 95% confidence interval (95% CI), 0.31-0.68] but not for gastric cardia adenocarcinoma (OR, 0.8; 95% CI, 0.54-1.19) compared to non-users.

The best known action of aspirin and other non-steroidal anti-inflammatory drugs (NSAIDs) is to block the enzyme cyclooxygenase (Cox), the rate limiting enzyme in the conversion of arachidonic acid to prostaglandins (7). Prostaglandins, such as PGE2, can promote cell proliferation, inhibit the immune response to malignant cells and may also inhibit apoptosis (8). Two Cox (Cox 1 and 2) genes have been cloned with approximately 60% sequence homology. Cox-1 is a housekeeping gene responsible for homeostatic functions such as maintaining the gastric mucosa, while Cox-2 is an inducible early response gene, which is dramatically upregulated during inflammation. Mechanisms underlying the association between Cox-2 overexpression and tumorigenic potential are thought to include inhibition of apoptosis and induction of cell proliferation.

In vitro experiments have shown NSAIDs to be anti-proliferative in some cell lines. Two NSAIDs, NS-398 and indomethacin, inhibited proliferation of two gastrointestinal cancer cell lines (MKN45 and CACO-2) that overexpressed the enzyme Cox-2 (9). However, these inhibitors exerted minimal effects on proliferation of other cell lines which expressed significantly lower levels of Cox-2.

Correspondence to: Dr Duminda Ratnasinghe, Cancer Prevention Studies Branch, Division of Clinical Sciences, National Cancer Institute, 6006 Executive Blvd., Suite 321, Bethesda, MD 20892-7058, USA

Abbreviations: Cox-2, cyclooxygenase-2; NSAIDs, non-steroidal anti-inflammatory drugs; OR, odds ratio; 95% CI, 95% confidence interval

Key words: immunohistochemistry, gastric cardia cancer, gastric corpus cancer, cyclooxygenase-2, NSAIDs

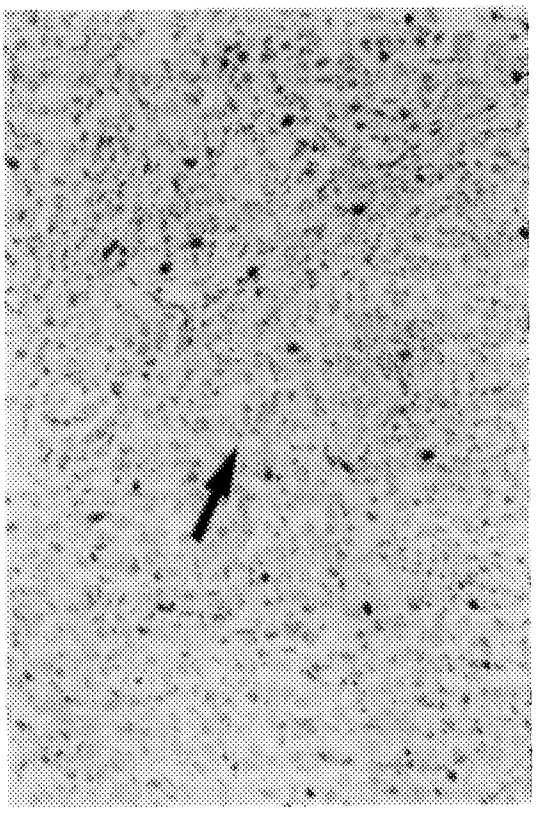

Figure 1. Adenocarcinoma of the gastric cardia with mild (1^+) brown Cox-2 staining in some tumor cells (black arrow). (Magnification x50).

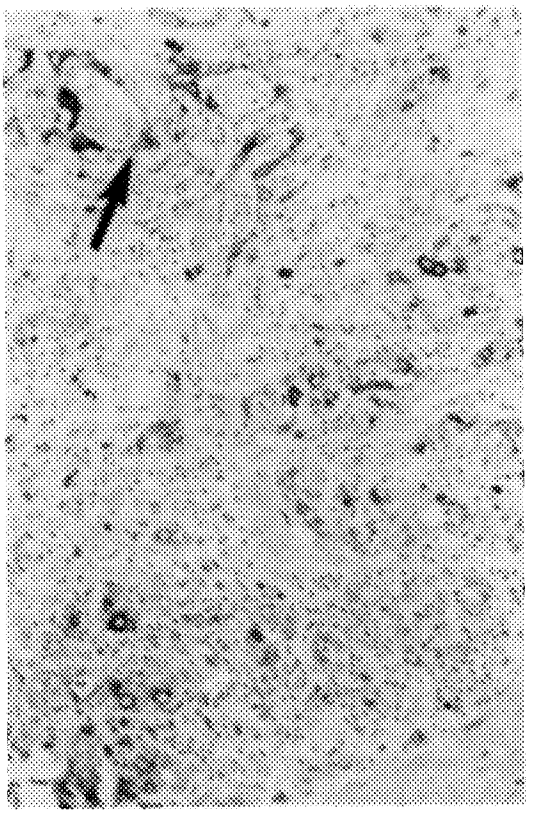

Figure 2. Adenocarcinoma of the gastric corpus with moderate (2^+) brown Cox-2 staining in well differentiated regions (black arrow). (Magnification x50).

Table I. Cox-2 expression in adenocarcinoma of the gastric cardia and gastric corpus.

	Number of specimens showing Cox-2 positivity (%)	Average intensity score in positive specimens
Normal epithelium (N=34)	0 (0)	-
Gastric cardia adenocarconoma (N=19)	7 (36)	1.5^+
Gastric corpus adenocarcinoma (N=15)	9 (60)	2^+
Stroma adjacent to normal epithelium (N=34)	34 (100)	2^{+a}
Stroma adjacent to tumor (N=34)	34 (100)	2^{+a}
Smooth muscle (N=34)	34 (100)	2.5^{+b}

[a]Staining in focal regions. [b]Average intensity in all smooth muscle cells.

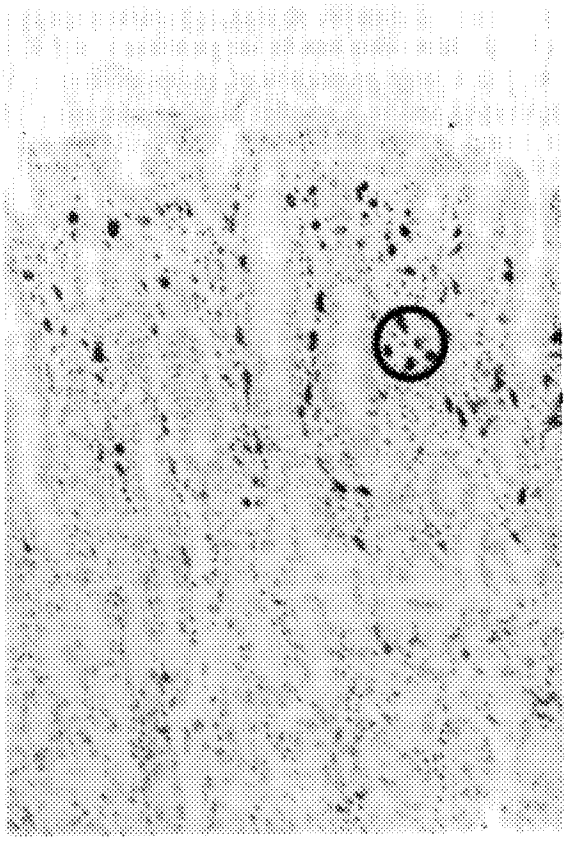

Figure 3. Histologically normal corpus mucosa negative for Cox-2. Intensely positive (3^+) inflammatory cells in the superficial aspects of the stomach mucosa are seen at the top (open circle). (Magnification x50).

Elevated levels of Cox-2 mRNA and protein, but not those of Cox-1, have been found in chemically induced rat colon carcinoma tissues (10) and in human colon carcinoma compared with normal mucosa (11). It is unknown whether Cox-2 is expressed in tumors of the gastric cardia. There is one report of Cox-2 overexpression in gastric corpus cancer (8). If Cox-2 is expressed in tumors of the gastric cardia as well as those of the gastric corpus, then these cancers may be targets for chemoprevention by NSAIDs use. Here we report an immunohistochemical study of Cox-2 expression in carcinoma of the gastric cardia and gastric corpus in tissue samples from a high risk Chinese population.

Materials and methods

Methods

Tissue samples. Surgical specimens of gastric cardia (N=19) and gastric corpus (N=15) adenocarcinomas were obtained from 34 patients resected at the Shanxi Cancer Hospital in Taiyuan, Shanxi Province, China. The 34 patients in this survey included 26 men and 8 women, with an average age of 58 years (range 40-72). Matched pairs of tumor and non-tumor tissue blocks were cut and formalin fixed within a few minutes of resection, then paraffin embedded for histological evaluation.

Immunohistochemistry. Formalin-fixed, paraffin-embedded tissues were cut to 4 μm sections and deparaffinized. Immunohistochemistry was performed with the immunoperoxidase technique using an anti-Cox 2 mouse monoclonal antibody from Transduction Laboratories (Lexington, KY) at a dilution of 1:400 with tyramide signal amplification (TSA-Indirect Kit, Dupont NEN Products, Boston, MA). The Vectastain Mouse Elite kit (Vector Laboratories, Burlingame, CA) was used as the secondary antibody, with diaminobenzidine (DAB) as the chromagen. Two cell lines, human colon cancer HT-29 and HCT 116 cells were used as positive and negative controls, respectively.

For each tissue specimen, the extent and intensity of staining with Cox-2 antibodies was graded as negative (-), mild (1^+), moderate (2^+) or intense (3^+). Separate intensity scores were recorded for epithelial, inflammatory, stromal and smooth muscle cells.

Results

Immunohistochemical analysis revealed positive staining of tumor cells with antibodies against Cox-2 in 36% of the gastric cardia cancer cases (Fig. 1) and 60% of the corpus adenocarcinomas (Fig. 2). Most of the gastric cardia cases were negative for Cox-2, while most of the stomach body adenocarcinomas were positive (Table I). Six of the seven positive cardia cancer cases (86%) were only mildly positive. Six of the nine positive corpus cancer cases (66%) were also only mildly positive. In contrast to squamous esophageal cancers (12), there was no correlation between differentiation status and Cox-2 expression.

The histologically normal epithelium from both the gastric cardia and corpus cancer (Fig. 3) cases were negative for Cox-2. Immunohistochemical staining was intensely positive in inflammatory cells located in the superficial aspects of the gastric mucosa (Fig. 3). Moderate to intense Cox-2 positivity was also present in stromal fibroblasts and smooth muscle cells near the epithelium in non-tumor and tumor tissue blocks.

Discussion

Using immunohistochemical techniques we found modestly elevated levels of Cox-2 protein in some tumors of human gastric cardia and corpus. Increased Cox-2 expression has also been previously identified in human colorectal cancers (11), gastric adenocarcinomas (8) and squamous esophageal cancers (12). Thus, overexpression of Cox-2 may be relatively common in epithelial cancers of the gastrointestinal tract. In all of our samples, including tumor and normal tissue sections from both gastric cardia and gastric corpus cancer cases, we observed staining of stromal fibroblasts, smooth muscle cells and inflammatory cells. The immunolocalization of Cox-2 in smooth muscle cells was similar to that reported by us previously (12). Furthermore, in contrast to esophageal squamous cell carcinomas that overexpress Cox-2 in well-differentiated tumors, there was no correlation between differentiation status and Cox-2 expression in adenocarcinomas of the cardia and corpus.

These results, although qualitative in nature, suggest that expression of the Cox-2 is elevated in some adenocarcinomas of the gastric cardia and gastric corpus cancers and that Cox-2 may be implicated in the pathogenesis of these adenocarcinomas. Cox-2 over-expression may contribute to enhanced synthesis of prostaglandin E_2, increased cell proliferation, immune-suppression and inhibition of apoptosis (8).

Consequently, selective inhibition of Cox-2 by aspirin and other NSAIDs may prove efficacious in the retardation of gastric cardia and gastric corpus cancer development. It is of interest to note that in the epidemiologic study reported by Farrow and colleagues (6) current users of aspirin were at reduced risk for gastric adenocarcinoma of the gastric corpus but not for the cardia. Our immunohistochemical survey also suggests that aspirin may be more efficacious in the retardation of gastric corpus adenocarcinoma development than cardia adenocarcinoma. However, this work needs to be confirmed by evaluating Cox-2 expression at the level of RNA in normal, preneoplastic and cancerous lesions in a larger number of subjects.

Acknowledgments

This project has been funded in whole or in part with Federal funds from the National Cancer Institute, National Institutes of Health, under Contract No. NO1-CO-56000.

References

1. Coleman MP, Esteve J, Damiecki P, Arslan A and Renard H: Trends in cancer incidence and mortality. IARC Scientific Publications No. 121. IARC, Lyon, pp193-224, 1993.
2. Parkin DM, Pisani P and Ferlay J: Estimates of the worldwide incidence of eighteen major cancers in 1985. Int J Cancer 54: 594-606, 1993.
3. Wanebo HJ, Kennedy BJ, Chmiel J, Steele G Jr, Winchester D and Osteen R: Cancer of the stomach. A patient care study by the American College of Surgeons. Ann Surg 218: 583-592, 1993.

4. Hu N, Taylor PR, Rao JY, Hemstreet GP, Liu SF, Zou XN, Mark SD and Dawsey SM: Quantitative fluorescence image analysis of DNA content and nuclear morphology on esophageal balloon cytology smears and subsequent development of esophageal and gastric cardia cancer in Linxian, China. Cancer Epidemiol Biomarkers Prev 7: 59-64, 1998.
5. Thun MJ, Namboodiri MM, Calle EE, Flanders WD and Heath CW Jr: Aspirin use and risk of fatal cancer. Cancer Res 53: 1322-1327, 1993.
6. Farrow DC, Vaughan TL, Hansten PD, Stanford JL, Risch HA, Gammon MD, Chow WH, Dubrow R, Ahsan H, Mayne ST, Schoenberg JB, West AB, Rotterdam H, Fraumeni JF Jr and Blot WJ: Use of aspirin and other nonsteroidal anti-inflammatory drugs and risk of esophageal and gastric cancer. Cancer Epidemiol Biomarkers Prev 7: 97-102, 1998.
7. Eberhart CE and Dubois RN: Eicosanoids and the gastrointestinal tract. Gastroenterology 109: 285-301, 1995.
8. Ristimaki A, Honkanen N, Jankala H, Sipponen P and Harkonen M: Expression of cyclooxygenase-2 in human gastric carcinoma. Cancer Res 57: 1276-1280, 1997.
9. Tsuji S, Kawano S, Sawaoka H, Takei Y, Kobayashi I, Nagano K, Fusamoto H and Kamada T: Evidence for involvement of cyclooxygenase-2 in proliferation of two gastrointestinal cancer cell lines. Prostaglandins Leukot Essent Fatty Acids 55: 179-183, 1996.
10. DuBois RN, Radhika A, Reddy BS and Entingh AJ: Increased cyclooxygenase-2 levels in carcinogen-induced rat colonic tumors. Gastroenterology 110: 1259-1262, 1996.
11. Eberhart CE, Coffey RJ, Radhika A, Giardiello FM, Ferrenbach S and DuBois RN: Up-regulation of cyclooxygenase 2 gene expression in human colorectal adenomas and adenocarcinomas. Gastroenterology 107: 1183-1188, 1994.
12. Ratnasinghe D, Tangrea J, Roth MJ, Dawsey S, Hu N, Anver M and Taylor PR: Expression of cyclooxygenase-2 in human squamous cell carcinoma of the esophagus; an immunohistochemical survey. Anticancer Res (In press).